

## Part I ABS SAMPLE TEST ITEMS

1. A +7.00 D lens has a real object located 20 cm from the lens. The conjugate image is:
- real and located 50 cm from the lens \*\*
  - virtual and located 50 cm from the lens
  - real and located 8.30 cm from the lens
  - virtual and located 8.30 cm from the lens
  - real and located 14.30 cm from the lens

**Classification: Optics (Geometrical): Ametropia**

2. A lens is made of glass with a refractive index of 1.65. What would be the refractive index for the ideal anti-reflection coating?
- 1.28 \*\*
  - 1.34
  - 1.41
  - 1.49
  - 1.65

**Classification: Optics (Physical): Ametropia**

3. An eye under the influence of an extremely strong miotic agent has a pupil diameter of 1 mm. The resolution of this eye is considered to be limited by:
- radial astigmatism
  - coma
  - diffraction \*\*
  - spherical aberration
  - depth of focus

**Classification: Optics (Physical): Ametropia**

4. The Jackson crossed cylinder subjective test is begun with a -1.00 -1.75 x 090 lens in front of a patient's eye. If the correcting cylinder power is changed to -0.75 x 090, then the spherical power should now be:
- 2.00 DS
  - 1.50 DS \*\*
  - 1.00 DS
  - 0.50 DS
  - +0.50 DS

**Classification: Optics (Physiological): Ametropia**

5. A 53-year-old male complains of occasional blur at distance and near. His visual acuities are 20/30 in each eye at distance and near with his present lens correction of +1.00 DS OU, Add +1.75 D. Your distance refraction for 20/20+ acuity is +1.50 DS OU. The BEST tentative Add for the new prescription will have a power of:

- a. +1.25 D
- b. +1.75 D \*\*
- c. +2.25 D
- d. +2.50 D

**Classification: Optics (Physiological): Ametropia**

6. A 21-year-old patient has a history of previously uncorrected simply hyperopic astigmatism of 3.00 D in each eye. Which of the following is MOST likely to be associated with the patient's refractive error?
- a. Eccentric fixation in one or both eyes
  - b. Meridional amblyopia in both eyes \*\*
  - c. Monocular central suppression
  - d. Anomalous correspondence
  - e. Strabismus secondary to the uncorrected refractive error

**Classification: Optics (Physiological): Ametropia**

7. In diabetic patients, a relative increase in which of the following refractive conditions is MOST associated with an increase in serum glucose levels?
- a. Hyperopia
  - b. Myopia \*\*
  - c. Astigmatism
  - d. Anisometropia

**Classification: Optics (Physiological): Ametropia**

8. A patient's corneal topography map shows steepening of the vertical meridian in a "bow tie" pattern. This indicates that the patient has:
- a. with-the-rule astigmatism \*\*
  - b. against-the-rule astigmatism
  - c. irregular astigmatism
  - d. a spherical cornea

**Classification: Optics (Physiological): Ametropia**

9. A Lensometer can be used for determining which 3 of the following parameters? **(SELECT 3)**
- a. Front surface power
  - b. Back surface power
  - c. Equivalent power
  - d. Neutralizing power \*\*
  - e. Prism power and base \*\*
  - f. Base curve
  - g. Cylinder axis \*\*

**Classification: Optics (Ophthalmic): Ophthalmic Optics / Spectacles**

10. Obliquely incident light passing through a spectacle lens contributes to which 4 of the following aberrations? **(SELECT 4)**
- a. Spherical aberration
  - b. Longitudinal chromatic aberration
  - c. Distortion \*\*
  - d. Coma \*\*
  - e. Radial astigmatism \*\*
  - f. Curvature of field \*\*

**Classification: Optics (Ophthalmic): Ophthalmic Optics / Spectacles**

11. Consider a patient with the following clinical data:

Spectacle prescription at the corneal plane: +7.00 -3.50 x 180  
Keratometry findings: 41.50 D @ 180, 44.00 D @ 090

A diagnostic rigid gas permeable contact lens for the patient has the following characteristics:

Power: +2.00 DS  
Base curve: 42.00 D (8.04 mm)

The expected over-refraction is:

- a. +4.50 -1.00 x 180 \*\*
- b. +4.50 -3.00 x 180
- c. +5.00 -1.50 x 180
- d. +5.50 -1.87 x 180

**Classification: Optics (Physiological): Contact Lenses**

12. A 71-year-old monocular low vision patient has a distance correction of +3.00 DS. Through a single +5.50 DS lens in the trial frame, he can barely read 2M print at 40 cm. What is the SMALLEST print you should expect him to barely read at a distance of 20 cm through a total lens power of +8.00 DS in the trial frame?

- a. 0.6M
- b. 0.8M
- c. 1.0M \*\*
- d. 2.0M
- e. 4.0M

**Classification: Optics (Physiological): Low Vision**

13. A head tilt toward the left shoulder is MOST likely due to a paresis of the right:

- a. inferior oblique
- b. superior oblique \*\*
- c. inferior rectus
- d. superior rectus

**Classification: Optics (Physiological): Accommodation / Vergence / Oculomotor Function**

14. You are performing the alternating cover test on a patient. Upon uncovering the right eye, the right eye moves down and out. Upon uncovering the left eye, the left eye moves up and out. Which of the following deviations is present?
- Double hyper
  - Eso, right hyper \*\*
  - Eso, right hypo
  - Exo, right hyper
  - Exo, right hypo

**Classification: Optics (Physiological): Accommodation / Vergence / Oculomotor Function**

15. A 65-year-old patient had a stroke and now manifests strabismus. In testing this patient for correspondence, the MOST likely result would be:
- unharmonious anomalous correspondence
  - harmonious anomalous correspondence
  - normal correspondence \*\*

**Classification: Optics (Physiological): Accommodation / Vergence / Oculomotor Function**

16. The near point of accommodation (NPA) of a patient wearing a +1.25 D Add over his best distance correction is 19 cm. If the Add is removed, the NPA would then be at approximately:
- 15 cm
  - 20 cm
  - 25 cm \*\*
  - 30 cm

**Classification: Optics (Physiological): Accommodation / Vergence / Oculomotor Function**

17. As an emmetropic patient fixates an object at 33 cm, you find retinoscopic neutrality at a distance of 67 cm. You should conclude that the accommodative response:
- lags behind the accommodative stimulus by 1.50 D \*\*
  - lags behind the accommodative stimulus by 3.00 D
  - leads the accommodative stimulus by 1.50 D
  - leads the accommodative stimulus by 3.00 D

**Classification: Optics (Physiological): Accommodation / Vergence / Oculomotor Function**

18. Physically identical gray spots are centered on 2 backgrounds, one white and the other black. A normal subject will perceive that the:
- gray spot on the white background is brighter
  - gray spot on the black background is brighter \*\*
  - gray spots on each background are equally bright

**Classification: Optics (Physiological): Perceptual Function / Color Vision**

19. How will a visually normal patient's foveal critical flicker frequency (CFF) compare when measured under low retinal illuminance versus when measured under high retinal illuminance?
- Higher foveal CFF under low retinal illuminance
  - Higher foveal CFF under high retinal illuminance \*\*
  - The same foveal CFF for low and high retinal illuminance

**Classification: Optics (Physiological): Perceptual Function / Color Vision**

20. The portion of the spectrum called blue-green by normals is MOST readily confused with the white portion for which of the following types of observers?
- Trichromats
  - Deuteranopes \*\*
  - Tritanopes

**Classification: Optics (Physiological): Perceptual Function / Color Vision**

21. Both a husband and wife pass standard color vision tests. If the wife's father has an inherited red-green color defect, what is the probability that the couple's daughter will be color defective?
- 0.00 \*\*
  - 0.25
  - 0.50
  - 1.00

**Classification: Optics (Physiological): Perceptual Function / Color Vision**

22. In a block of 100 trials of a yes/no signal detection experiment, the signal is absent on 10 trials. The observer has 80 hits and 5 false alarms. How many responses are correct rejections?
- 0
  - 5 \*\*
  - 10
  - 15

**Classification: Optics (Physiological): Perceptual Function / Color Vision**

23. When measured with Teller acuity cards, the grating acuity of a 10-month-old infant is expected to be approximately:
- 10 cycles per degree \*\*
  - 30 cycles per degree
  - 50 cycles per degree

- d. 70 cycles per degree

**Classification: Optics (Physiological): Visual and Human Development**

24. When an elderly patient is driving toward a sunset, his vision is disturbed MOST by the normal aging changes in:
- a. tear film
  - b. pupil size
  - c. dark adaptation
  - d. the crystalline lens \*\*

**Classification: Optics (Physiological): Visual and Human Development**

25. The MOST frequent etiology of a unilateral or bilateral proptosis in an adult is:
- a. orbital pseudotumor
  - b. cavernous hemangioma
  - c. painful ophthalmoplegia
  - d. Graves disease \*\*

**Classification: Pathology: Lids / Lashes / Lacrimal System / Ocular Adnexa / Orbit**

26. A 21-year-old patient has an enlarging, elevated reddish-blue eyelid lesion of recent onset. As the next step in evaluating this patient, you should order which of the following laboratory tests?
- a. HIV ELISA \*\*
  - b. C-reactive protein
  - c. Hemoglobin A<sub>1c</sub>
  - d. Alanine transaminase

**Classification: Pathology: Lids / Lashes / Lacrimal System / Ocular Adnexa / Orbit**

27. The sensation of corneal pain is PRIMARILY transmitted through which of the following nerves?
- a. Infraorbital
  - b. Lacrimal
  - c. Nasociliary \*\*
  - d. Oculomotor

**Classification: Anatomy (Gross): Conjunctiva / Cornea / Refractive Surgery**

28. Which of the following preservatives is MOST likely to disrupt the corneal epithelium?
- a. Benzalkonium chloride \*\*
  - b. Chlorobutanol
  - c. Sorbic acid
  - d. Chlorhexidine

**Classification: Pharmacology: Conjunctiva / Cornea / Refractive Surgery**

29. A 72-year-old female manifests lenticular changes and an increase in myopia. Which of the following types of cataracts is MOST likely responsible for these clinical signs?
- Anterior cortical
  - Nuclear \*\*
  - Cerulean
  - Posterior polar

**Classification: Pathology: Lens / Cataract / IOL / Pre- and Post-operative Care**

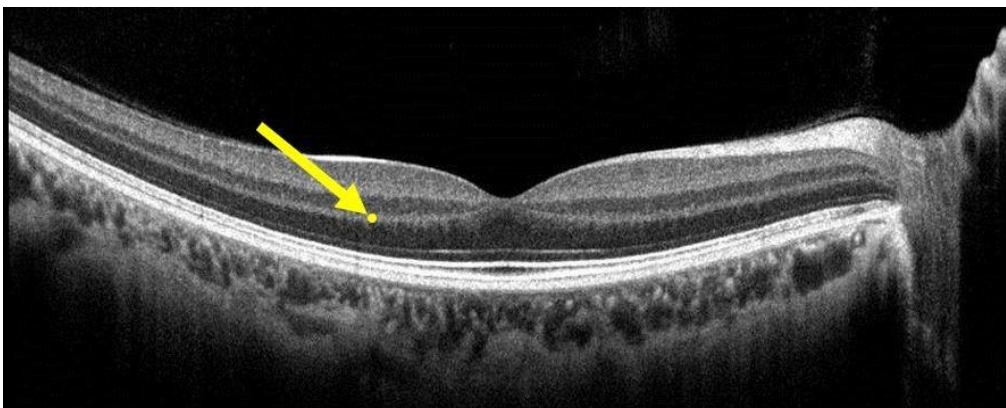
30. A 33-year-old female has iridocyclitis. Slit lamp examination findings include large, mutton-fat keratic precipitates. The clinical procedure MOST likely to confirm your diagnosis is:
- a chest x-ray \*\*
  - an upper GI series
  - an antinuclear antibody test
  - urinalysis

**Classification: Pathology: Episclera / Sclera / Anterior Uvea**

31. Occlusion of the central retinal artery will MOST likely cause necrosis of which of the following retinal layers?
- Inner nuclear
  - Ganglion cell \*\*
  - Retinal pigmented epithelium
  - Outer nuclear

**Classification: Anatomy (Gross): Vitreous / Retina / Choroid**

32. Consider the OCT image shown below, and the yellow dot to which the arrow is pointing:



The yellow dot is located in which retinal layer?

- Inner plexiform

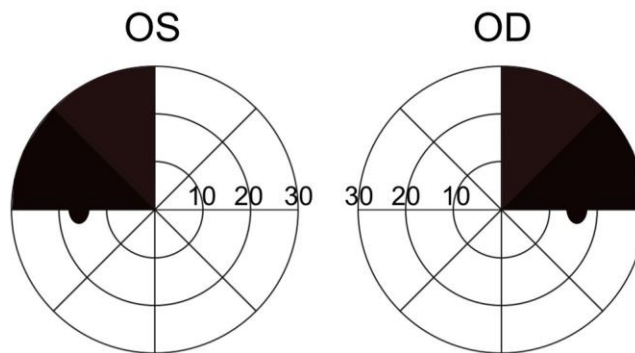
- b. Outer plexiform \*\*
- c. Inner nuclear
- d. Outer nuclear

**Classification: Anatomy (Gross): Vitreous / Retina / Choroid**

33. An incongruous homonymous hemianopia that is most dense superiorly is usually indicative of a lesion in which cerebral lobe?
- a. Frontal
  - b. Temporal \*\*
  - c. Parietal
  - d. Occipital

**Classification: Pathology: Optic Nerve / Neuro-Ophthalmic Pathways**

34. Consider the visual field defect shown in the figure below:



Which of the following conditions is the MOST likely etiology of this visual field defect?

- a. Aneurysm of the basilar artery
- b. Left optic nerve glioma
- c. Right occipital lobe tumor
- d. Pituitary adenoma \*\*

**Classification: Pathology: Optic Nerve / Neuro-Ophthalmic Pathways**

35. When you ask a patient to shrug his shoulders, which cranial nerve are you evaluating?
- a. Vagus
  - b. Glossopharyngeal
  - c. Spinal accessory \*\*
  - d. Hypoglossal
  - e. Trigeminal

**Classification: Anatomy (Gross): Systemic Health**



36. A 31-year-old female is deaf in her right ear and is unable to close her right eye but has no loss of touch sensation on the right side of her face. The MOST likely site of a single lesion that would account for her symptoms is the:

- a. superior orbital fissure
- b. cavernous sinus
- c. internal auditory meatus \*\*
- d. stylomastoid foramen
- e. crus cerebri

**Classification: Anatomy (Neuroanatomy): Systemic Health**

37. Which of the following changes in plasma ion concentration is the major stimulus for parathyroid hormone secretion?

- a. An increase in calcium
- b. A decrease in calcium \*\*
- c. An increase in sodium
- d. A decrease in potassium

**Classification: Physiology: Systemic Health**

38. Which of the following cell types is capable of becoming a plasma cell?

- a. Monocyte
- b. Lymphocyte \*\*
- c. Eosinophil
- d. Neutrophil

**Classification: Immunology: Systemic Health**

39. Which type of antibody is involved in atopic disease?

- a. IgA
- b. IgE \*\*
- c. IgG
- d. IgM

**Classification: Immunology: Systemic Health**

40. Which of the following tests would BEST differentiate staphylococci from streptococci?

- a. Catalase \*\*
- b. Oxidase
- c. Gram stain
- d. Giemsa stain

**Classification: Microbiology: Systemic Health**

41. Which 3 of the following organisms are gram negative? **(SELECT 3)**

- a. *Neisseria gonorrhoeae* \*\*
- b. *Pseudomonas aeruginosa* \*\*
- c. *Staphylococcus aureus*
- d. *Moraxella lacunata* \*\*
- e. *Corynebacterium diphtheria*

**Classification: Microbiology: Systemic Health**

42. Tumors originating in which of the following organs typically do NOT metastasize?

- a. Lung
- b. Breast
- c. Colon
- d. Brain \*\*

**Classification: Pathology: Systemic Health**

43. Ankylosing spondylitis INITIALLY leads to inflammation and functional change within which skeletal region?

- a. Cervical
- b. Thoracic
- c. Sacroiliac \*\*
- d. Coccyx

**Classification: Pathology: Systemic Health**

44. Hematuria is MOST likely the result of which of the following conditions?

- a. Cystitis \*\*
- b. Hepatitis
- c. Pancreatitis
- d. Hemosiderosis

**Classification: Pathology: Systemic Health**

45. All of the following are extraintestinal manifestations of idiopathic inflammatory bowel disease EXCEPT:

- a. arthritis
- b. hepatic disease
- c. ocular inflammation
- d. pulmonary infections \*\*

**Classification: Pathology: Systemic Health**

46. Which of the following laboratory tests will yield abnormal results in a patient who has liver damage?

- a. Creatine phosphokinase
- b. Blood urea nitrogen
- c. Uric acid
- d. Bilirubin \*\*

**Classification: Pathology: Systemic Health**

47. A child with mental retardation, single palmar creases, low set ears, prominent epicanthal folds, and short stature MOST likely has:

- a. osteogenesis imperfecta
- b. fetal alcohol syndrome
- c. trisomy 21 \*\*
- d. cretinism

**Classification: Pathology: Systemic Health**

48. When delivering an intramuscular injection into the deltoid muscle of an adult using a 5.0 cc syringe, which of the following gauge needles is MOST appropriate?

- a. 18 gauge
- b. 23 gauge \*\*
- c. 27 gauge
- d. 30 gauge

**Classification: Pharmacology: Systemic Health**

49. Which of the following drugs acts by selective stimulation of  $\beta_2$ -adrenergic receptors?

- a. Theophylline
- b. Isoproterenol
- c. Norepinephrine
- d. Albuterol \*\*

**Classification: Pharmacology: Systemic Health**

50. Which 2 of the following drugs inhibit the synthesis of the bacterial cell wall? **(SELECT 2)**

- a. Doxycycline
- b. Cephalexin \*\*
- c. Ciprofloxacin
- d. Erythromycin
- e. Amoxicillin \*\*

**Classification: Pharmacology: Systemic Health**