

TMOD Examination - Minicase

Demographics

66-year-old white male; retired

Chief complaint

floaters OD > OS

Patient ocular history

uncomplicated cataract extraction with IOL implant OD, OS 1 year ago

Patient medical history

hypertension; hypercholesteremia

Medications taken by patient

hydrochlorothiazide; atenolol; Lipitor®; multivitamin

Patient allergy history

penicillin

Clinical findings

BVA:	<u>Distance</u>	<u>Near (with +2.50 Add)</u>
OD:	20/25+1	20/20-1
OS:	20/20	20/20

Pupils: PERRL, negative RAPD

EOMs: full, no restrictions

Confrontation fields: full to finger counting OD, OS

Slit lamp:

lids/lashes/adnexa: normal OD, OS

conjunctiva: normal OD, OS

cornea: clear with well healed incision OD, OS

anterior chamber: deep and quiet OD, OS

iris: normal OD, OS

lens: well-centered IOL with clear and intact posterior capsule OD, OS

vitreous: see **Image 1 OD**, clear OS

IOPs: 10 mmHg OD, 11 mmHg OS @ 2:50 PM by non-contact tonometry

Fundus OD:

C/D: see **Image 1**

macula: normal

posterior pole: normal

periphery: difficult to view

Fundus OS:

C/D, macula, posterior pole: see **Image 2**

periphery: unremarkable

Image 1

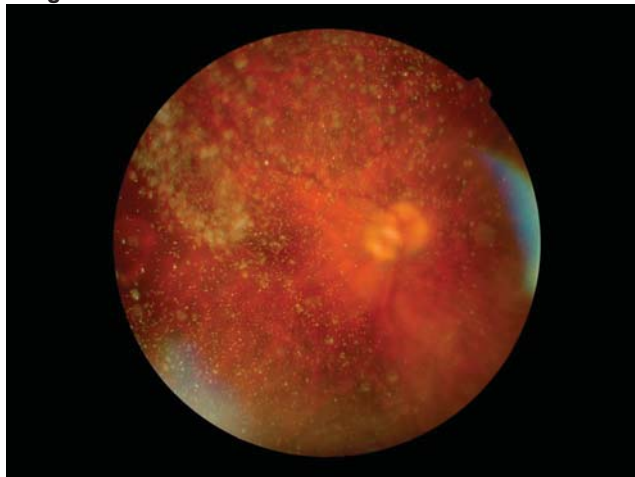
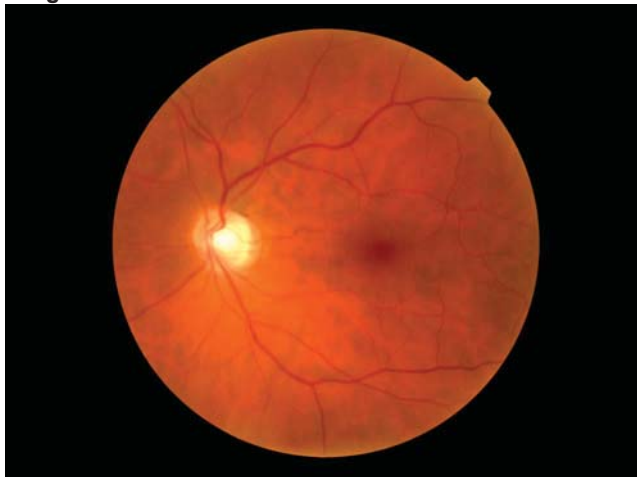

Image 2



1. Which of the following is the most likely diagnosis of the patient's ocular findings OD in *Image 1*? (Diagnosis)

- a. Vitritis
- b. Chorioretinitis
- c. Vitreal syneresis
- d. Posterior vitreous detachment
- e. Asteroid hyalosis
- f. Weiss ring
- g. Persistent hyaloid artery
- h. Endophthalmitis

2. The findings visible in *Image 1* are most likely: (Clinical Correlation of Basic Science Principles)

- a. white blood cells.
- b. calcium soaps.
- c. condensed vitreal tissue.
- d. red blood cells.
- e. remnant embryonic vessel.
- f. retained lens material.
- g. pigment cells.

3. Which of the following is the most appropriate management for this patient's ocular findings OD? (Treatment/ Management)

- a. Barrier peripheral laser
- b. Pars plana vitrectomy
- c. Oral prednisone 60 mg per day
- d. Vitreal tap and culture
- e. Intravenous Vancomycin 1g q.12h.
- f. No treatment needed